

MODULE 5 L07

Upper Limb Blood Vessels

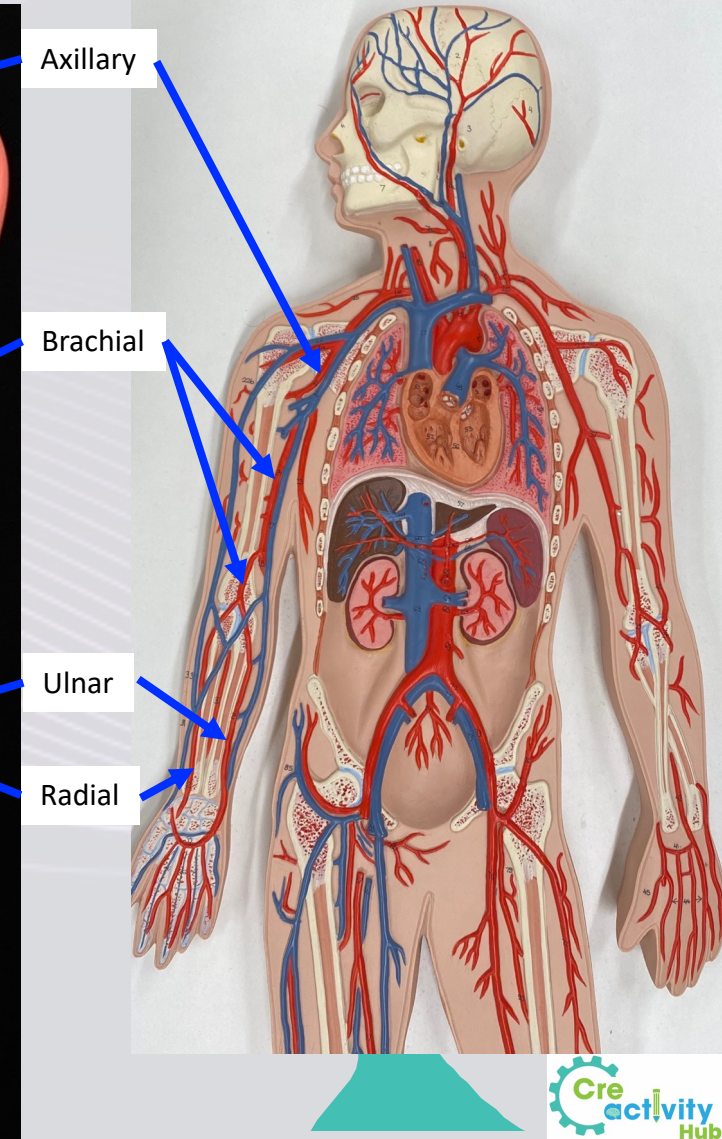
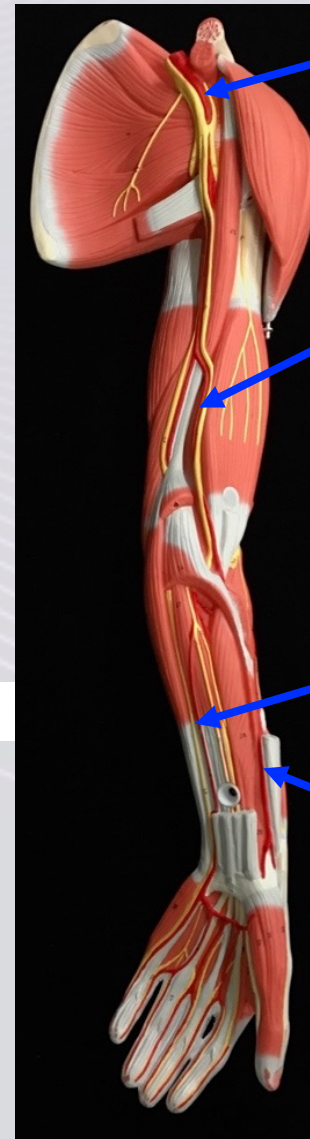
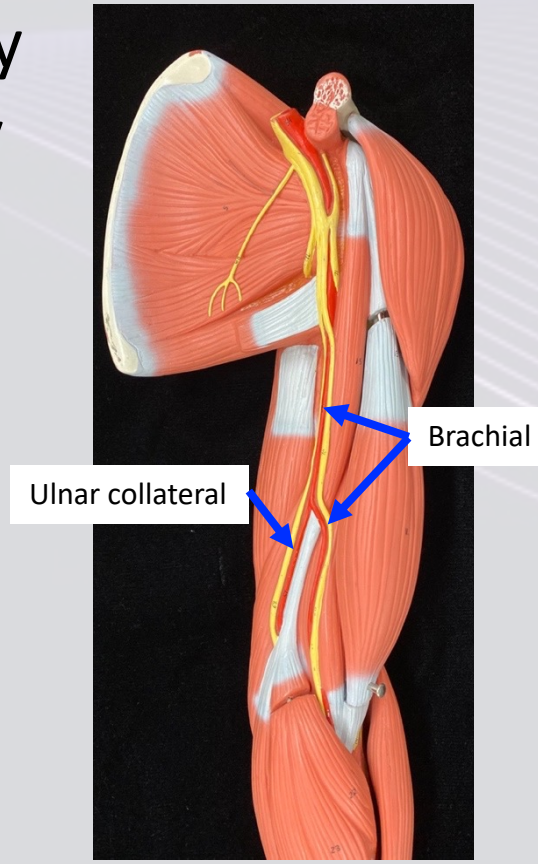
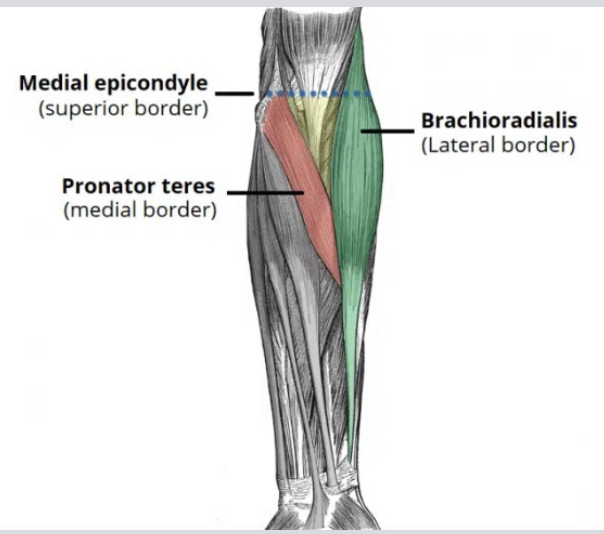
Dr. Lisa Brinn

lbrinn@fiu.edu



E. Upper Limb Arteries

- Subclavian artery
 - Axillary artery
 - Brachial artery
 - ❖ Radial artery
 - ❖ Ulnar artery
- Pass first rib
- Teres major



Upper Limb Veins

